

Five-Year Outcome of LASIK for Myopia

Naoko Kato, MD, PhD^{1,2} Ikuko Toda, MD, PhD,^{1,2} Yoshiko Hori-Komai, MD, PhD,^{1,2} Chikako Sakai, BS,¹ Kazuo Tsubota, MD, PhD²

Purpose: To investigate the efficacy and safety of LASIK over a 5-year postoperative period.

Design: Observational case series.

Participants: We examined 779 eyes in 402 patients with myopia or myopic astigmatism who underwent LASIK to correct their refractive errors and received regular postoperative assessments for 5 years.

Methods: Postoperative examinations were performed 1 day; 1 week; 1, 3, and 6 months; and 1, 2, 3, 4, and 5 years after LASIK surgery.

Main Outcome Measures: We evaluated changes in uncorrected visual acuity (UCVA) (logarithm of the minimum angle of resolution [logMAR]), manifest refraction, best-corrected visual acuity (BCVA) (logMAR), intraocular pressure, corneal thickness, corneal endothelial cell counts, and complications.

Results: Preoperative UCVA of 1.27 improved to -0.03 at 1 day after surgery and -0.08 at 1 month and revealed minimal but significant decreases thereafter. Postoperative manifest refraction was also improved by surgery, showing minimal but significant regression after 1 year. Final BCVA loss was seen in 10 eyes of 7 patients; in 7 cases, there were obvious reasons such as the progression of cataracts in 3 eyes, epithelial disintegrity due to dry eye in 2 eyes, irregular astigmatism due to flap striae in 1 eye, and age-related macular dystrophy in 1 eye. Intraocular pressure and corneal thickness decreased by 4.0 mmHg and 76.9 μm , respectively, due to surgery, but remained stable throughout the follow-up period. Corneal endothelial cell counts (2689.0 ± 232.9 cells/ mm^2 before surgery) showed a statistically significant decrease at 5 years after surgery (2658.0 ± 183.1 cells/ mm^2 ; 1.2% loss for 5 years), likely within the range due to physiological age-related loss. No serious, vision-threatening, irreversible complication such as keratectasia or progressive endothelial cell loss was observed.

Conclusion: LASIK surgery is an effective and safe procedure for correcting myopia/myopic astigmatism as long as inclusion and exclusion criteria are strictly respected. However, minimal regression occurred during the 5-year investigative period. *Ophthalmology* 2008;115:839–844 © 2008 by the American Academy of Ophthalmology.



Since the development of LASIK by Pallikaris in 1990, the population eligible for the procedure has continued to increase.^{1,2} LASIK is now one of the most popular corneal refractive surgeries.^{3–5} Creating a corneal flap with an intact epithelial layer and repositioning it after stromal ablation with an excimer laser eliminates the release of proinflammatory cytokines and growth factors from the epithelial cells, making LASIK a painless procedure and minimizing postoperative inflammation and wound-healing responses, resulting in a low frequency of stromal haze.^{6–11}

The efficacy and safety of LASIK have been reported by several investigators; however, most of these reports have summarized postoperative outcomes for a relatively short duration, typically from 1 to 18 months.^{11–23} O'Doherty et al reported long-term results of LASIK (5 years); however, only 49 patients were observed.¹³ Sekundo et al also re-

ported 6-year outcomes of LASIK surgery; however, only 33 eyes were examined.²⁴ Long-term outcomes in a large number of patients have not been reported.

We have performed LASIK at our institute since 1997 and have made an effort to follow up and record the postoperative conditions of our patients for as long as possible. We are now able to summarize postoperative data for 779 eyes that were continuously followed for 5 years. To our knowledge, this is the first report of long-term postoperative outcomes of myopic LASIK in a large number of cases.

Materials and Methods

Patients

The study protocol was conducted in accordance with the tenets of the Declaration of Helsinki. Written informed consent was obtained from all patients.

Drs Kato and Toda contributed equally to the work.

Correspondence and reprint requests to Naoko Kato, MD, PhD, Department of Ophthalmology, School of Medicine, Keio University, Shinanomachi 35, Shinjuku-ku, Tokyo 160-8582, Japan. E-mail: naokato@sc.itc.keio.ac.jp.

Originally received: March 27, 2007.

Final revision: June 18, 2007.

Accepted: July 9, 2007.

Available online: September 27, 2007.

Manuscript no. 2007-417.

¹ Minamiaoyama Eye Clinic, Tokyo, Japan.

² Department of Ophthalmology, School of Medicine, Keio University, Tokyo, Japan.

Seven hundred seventy-nine eyes of 402 patients (221 male, 181 female; mean age, 34.6 ± 8.3 years; mean subjective refraction, -6.40 ± 2.58 diopters [D]; range of subjective refraction, -0.75 to -14.50 D) who underwent LASIK between December 1997 and March 2002 at Minamiaoyama Eye Clinic and regularly returned for postoperative examination were enrolled in this study. We performed LASIK surgery on 21 300 eyes from 1997 until the end of 2006, and the total number of eyes that underwent LASIK between December 1997 and March 2002 was 11 722. Thus, we analyzed outcomes only from patients who regularly and continuously returned for postoperative examinations for up to 5 years after surgery. The number of eyes in which we could assess continuous postoperative outcomes was limited to 779. No patient revealed any abnormal finding on routine preoperative ophthalmologic examination.

Our exclusion criteria were myopia > -12.0 D, insufficient corneal thickness for laser ablation (estimated total corneal thickness < 400 μm and estimated residual thickness of the stromal bed < 250 μm after laser ablation), or preoperative detection of forme fruste keratoconus by videokeratography indices. Eyes with endothelial cell counts < 1500 cells/ mm^2 were also excluded.

LASIK Procedure

LASIK was performed on both eyes of each patient successively using an identical method. Before the surgery, we measured the corneal thickness using an AL-2000 pachymeter (Tomey, Aichi, Japan) at the corneal apex. The corneal flap was created using an LSK-One (Moria, Antony, France; 417 eyes), M2 (Moria; 2 eyes), MK-2000 (Nidek, Aichi, Japan; 356 eyes), or Flapmaker (Solan Ophthalmic Products, Jacksonville, FL; 4 eyes) microkeratome. After the flap was created, the thickness of the stroma underneath was measured using the AL-2000, and the estimated flap thickness was calculated by subtracting the stromal thickness from the total corneal thickness. Laser ablation was then performed using APEX PLUS (Summit, Waltham, MA; 117 eyes) or EC-5000 (Nidek; 662 eyes) excimer lasers. The interface between the flap and stromal bed was irrigated with balanced salt solution containing 0.6-mg/ml gentamicin (Gentacin, Schering-Plough K.K., Osaka, Japan) and 0.4-mg/ml methylprednisolone (Solu-Medrol, Pfizer, Tokyo, Japan). After surgery, low-dose steroid (0.1% Flumetholone, Santen, Osaka, Japan), antibiotic (Tarivid or Cravit, Santen), and 0.3% hyaluronic acid (Hyalein, Santen) eyedrops were prescribed 5 times per day and discontinued at 1 week postoperatively.

Postoperative Examinations

Postoperative examinations were performed 1 day; 1 week; 1, 3, and 6 months; 1 year; and every year after that up to 5 years after surgery. Uncorrected visual acuity (UCVA), best-corrected visual acuity (BCVA), manifest refraction, intraocular pressure (IOP) assessed by noncontact tonometry, corneal thickness, and corneal endothelial cell count were measured, in addition to the usual ophthalmologic and fundoscopic examinations. Corneal thickness was measured using the AL-2000 at the corneal apex. Corneal endothelial cells were counted using a specular microscope (Noncon Robo SP-9000, Konan, Hyogo, Japan).

Patient Satisfaction

We surveyed the overall patient satisfaction with the outcome of LASIK using grades of 1 for very satisfied; 2, satisfied as expected; 3, not very satisfied; and 4, regretted undergoing LASIK.

Statistical Analyses

Paired *t* tests were used for analyses of changes in UCVA, BCVA, corneal thickness, and corneal endothelial counts. $P < 0.05$ was deemed statistically significant.

Results

Diameter of the Ablation Zones

The spherical equivalent (SE) of the target for the correction of refractive error was -6.30 ± 2.59 D (range, -0.5 to -14.0). In 765 eyes (98.2%), the laser ablation was planned to target full correction. Mean diameters of the ablated area were 6.06 ± 0.22 mm (range, 5.00–6.50) in the optical area and 6.97 ± 0.17 mm (range, 5.70–7.50) when the transitional area was included.

Visual Acuity

The UCVA (logarithm of the minimum angle of resolution [logMAR]) of the patients was 1.27 (range, 0.2–2.0) preoperatively and improved to -0.03 on 1 day and -0.07 at 1 week, reached -0.08 at 1 month, and was not statistically changed up to 1 year after surgery. Thereafter, UCVA showed continuous very small but statistically significant decreases, reaching -0.03 at 5 years after surgery (Fig 1A). Uncorrected visual acuities (logMAR) better than 0.0 and better than 0.2 were obtained in 85% and in 94%, respectively, of operated eyes at 1 month after surgery and also showed minimal but statistically significant decreases for up to 5 years after surgery (Fig 1B).

The final BCVA at the 5-year examination improved by 2 lines in 8 eyes (1.3%) and was unchanged in 761 eyes (97.7%; Fig 2). However, 10 eyes lost ≥ 2 lines (1.3%) of BCVA. Three eyes in 2 patients revealed the progression of cataracts, 2 eyes of 2 patients revealed corneal epithelial disintegrity due to dry eye, 1 eye had suspected macular degeneration, and 1 eye showed irregular astigmatism due to striae of the corneal flap. We could not find any obvious cause for the decrease in BCVA in the remaining 3 eyes in 2 patients (Table 1). The manifest refraction, corneal power, and corneal topography showed that none of these 3 eyes demonstrated keratectasia.

Refraction

The manifest refraction of -6.40 ± 2.58 D preoperatively was improved to 0.07 ± 0.49 D at 1 week after surgery. Thereafter, the manifest refraction continued to regress minimally but statistically significantly up to the 5-year examination (Fig 3A). Of the operated eyes, 86% had manifest refraction within ± 0.5 D and 96% were within ± 1.0 D at 1 week after surgery, although both frequencies decreased thereafter (Fig 3B).

We examined the achievement of correction at 3 months and at 5 years after surgery (Fig 4A, B, respectively [available at <http://aaojournal.org>]). The difference between the attempted and achieved corrections was within ± 0.5 D in 602 eyes (82.6%), within ± 1.0 D in 679 eyes (93.1%), and within ± 2.0 D in 718 eyes (98.5%) in the 729 eyes that could be examined at 3 months postoperatively. The difference between the attempted and achieved corrections was within ± 0.5 D in 586 eyes (75.2%), within ± 1.0 D in 693 eyes (89.0%), and within ± 2.0 D in 763 eyes (97.9%), among all 779 eyes included in this investigation.

We also examined the correlation between the preoperative refractive error and residual refractive error at 3 months and at 5 years after surgery (Fig 4C, D, respectively). There were positive correlations between the preoperative and residual refractive errors

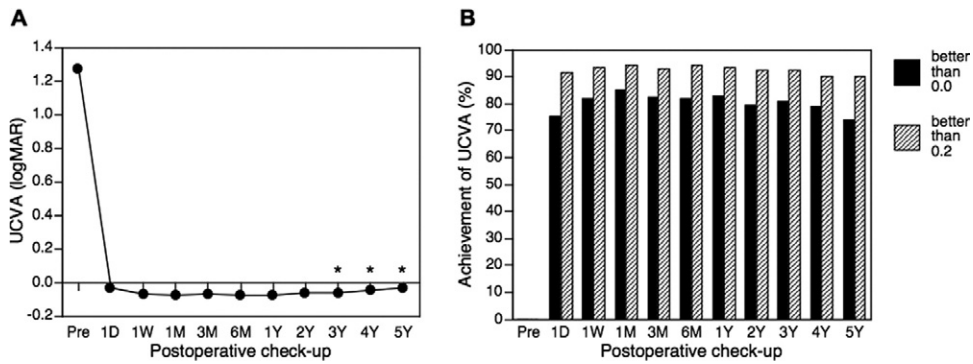


Figure 1. Changes in uncorrected visual acuity (UCVA). **A**, The UCVA (logarithm of the minimum angle of resolution [logMAR]) was improved at 1 day after surgery and was stable until 1 year after surgery. Thereafter, UCVA showed a minimal but statistically significant decrease. **B**, Numbers of patients who had UCVA better than 0.0 and 0.2 were 85% and 94%, respectively, at 1 month after surgery. This also showed a minimal but statistically significant decrease up to 5 years. D = day; M = month; pre = preoperative examination; W = week; Y = year. * $P < 0.05$ compared with UCVA at 3 months after surgery.

at both times (3 months: $y = 0.043x + 0.138$, $r^2 = 0.042$, $P < 0.001$; Fig 4C) (5 years: $y = 0.058x$, $r^2 = 0.067$, $P < 0.001$; Fig 4D).

Intraocular Pressure

The IOP was 13.7 ± 2.5 mmHg (range, 7.9–21.5) preoperatively. It decreased to 9.7 ± 2.0 mmHg (range, 5.0–20.7) at 1 week and 9.4 ± 2.0 mmHg (range, 4.8–20.7) at 1 month after surgery and did not change thereafter (Fig 5 [available online at <http://aaojournal.org>]).

Corneal Thickness

The corneal thickness was 542.9 ± 30.1 μm (range, 467–655) preoperatively. It decreased to 466.0 ± 41.8 μm (range, 368–576) at 3 months after surgery and did not change significantly thereafter (Fig 6 [available at <http://aaojournal.org>]).

Corneal Endothelial Cell Count

Average corneal endothelial cell counts were 2689.0 ± 232.9 cells/ mm^2 before surgery, 2688.9 ± 371.6 cells/ mm^2 at 3 months, 2693.8 ± 254.9 cells/ mm^2 at 6 months, 2690.3 ± 197.6 cells/ mm^2 at 1 year, 2682.1 ± 157.0 cells/ mm^2 at 2 years, 2671.5 ± 143.0 cells/ mm^2 at 3 years, 2668.8 ± 165.4 cells/ mm^2 at 4 years, and 2658.0 ± 183.1 cells/ mm^2 at 5 years after surgery (Fig 7 [available at <http://aaojournal.org>]). The corneal endothelial cell counts showed no significant loss up to the 4-year examination. However, the corneal endothelial cell counts at 5 years showed a significant decrease compared with the preoperative value ($P = 0.006$).

at both times (3 months: $y = 0.043x + 0.138$, $r^2 = 0.042$, $P < 0.001$; Fig 4C) (5 years: $y = 0.058x$, $r^2 = 0.067$, $P < 0.001$; Fig 4D).

Complications

For intraoperative complications, epithelial defects were observed in 24 eyes (3.1%), and a free flap was observed in 1 eye (0.1%). One eye (0.1%) required intraoperative lateral canthotomy due to a small palpebral fissure.²⁵ Diffuse lamellar keratitis was diagnosed in 16 eyes (2.1%) on the first postoperative day, and 1 eye required irrigation of the flap–stroma interface due to the progression of inflammation. Microstriae were observed in 104 eyes (13.3%), of which 26 (3.3%) were diagnosed on the first postoperative day. Most of those microstriae did not affect visual acuity (VA); thus, they were followed without surgical intervention. Four eyes required repositioning of the corneal flap due to visual impairment because of irregular astigmatism. Epithelial ingrowth was observed in 21 eyes (2.7%), but only in 1 eye was surgical removal required. Neither corneal haze nor keratectasia was observed in any eye.

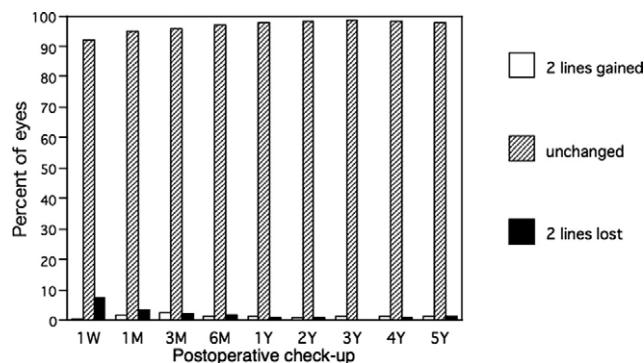


Figure 2. Changes in best-corrected visual acuity (BCVA). The frequency of eyes with BCVA that lost 2 lines was 7.3% of the operated eyes at 1 week after surgery. However, the frequency decreased thereafter and declined to 1.3% at 5 years after surgery. M = month; W = week; Y = year.

Enhancement

Additional surgeries to correct postoperative refractive error were performed in 136 eyes (17.5%). Causes for additional surgeries were decreased UCVA due to regression in 93 eyes, undercorrection in 38 eyes, overcorrection in 4 eyes, and astigmatism induced by the primary surgery in 1 eye. The previous corneal flap was lifted in 130 eyes (95.5%), whereas a new flap was created in 6 eyes (4.5%). The timing for enhancement was 2.5 ± 1.6 years (range, 21 days–5 years) after the primary surgery. However, no correlation was found between the preoperative manifest refraction and frequency of additional laser ablation.

Patient Satisfaction

We found no significant difference in patient satisfaction from 1 month to 5 years after surgery (Fig 8 [available at <http://aaojournal.org>]).

Table 1. Cases of the Loss of 2 Lines of Best-Corrected Visual Acuity (BCVA) at 5 Years after Surgery

Case	Gender	Age	R/L	Preoperative BCVA (logMAR)	Postoperative BCVA (logMAR)	Cause
1	F	22	L	-0.1	0.1	Striae
2	F	53	R	0.0	0.2	Progression of cataract
			L	0.0	0.2	Progression of cataract
3	F	23	R	-0.2	0.0	Dry eye
4	F	45	L	-0.2	0.0	Dry eye
5	F	40	R	-0.2	0.0	Unknown (possibly irregular astigmatism)
			L	-0.2	0.0	Unknown (possibly irregular astigmatism)
6	M	35	R	-0.2	0.1	Progression of cataract
7	M	34	L	-0.2	0.0	Unknown
8	M	39	L	-0.2	0.2	Age-related macular dystrophy

F = female; L = left eye; logMAR = logarithm of the minimum angle of resolution; M = male; R = right eye.

Discussion

Post-LASIK refractive results continued to be stable for a long time after the initial surgery, although minimal regression was observed by 1 year after surgery. The maintenance of postoperative refractive error within ± 1.0 D in about 90% and within ± 2.0 D in 97.9% of all operated eyes indicated that the predictability and stability of the surgery were good. A decreased BCVA of >2 lines was observed in 10 eyes (1.3%); however, in 7 of these, there were obvious causes other than LASIK (e.g., progression of cataracts, epithelial impairment due to dry eye, macular degeneration). No eye revealed irreversible complications such as keratectasia, corneal stromal haze affecting VA, or severe corneal endothelial cell loss. Approximately 90% of the patients answered that they were satisfied or very satisfied with the outcome of the surgery throughout the examination period.

We always instruct all patients to undergo every postoperative examination for at least 5 years; however, the frequencies with which patients visited our institute for postoperative examinations were 94% at 1 week after surgery, 87% at 1 month, 73% at 3 months, 55% at 6 months, and 46% at 1 year and continued to decline thereafter. Our most

recent data indicate that the frequency of postoperative examination fell to 9.3% at 5 years after surgery. This declining frequency of postoperative examination surely affects the incidence of regression, enhancement, and patient satisfaction. There are many reasons why patients fail to return for postoperative examination. Some who did not return to our institute were seen at other institutes inside and outside the country because of the patients' personal circumstances. However, the majority of patients simply disregarded our recommendation for follow-up examinations, probably because they felt no need for follow-up. Thus, it would seem that those who were satisfied with the results of the surgery tended to forget or ignore the schedule for postoperative examination, whereas those who experienced irregularities in their visual performance such as poor UCVA due to undercorrection/regression or discomfort due to dry eye after surgery frequently came back to the institute. As a result, the true incidence of regression, enhancement, and patient satisfaction among all patients who undergo LASIK is likely to differ somewhat from what we report here.

We planned full correction of myopic astigmatism in 98% of enrolled eyes. The UCVA and manifest refraction showed dramatic recovery just after surgery; however, a

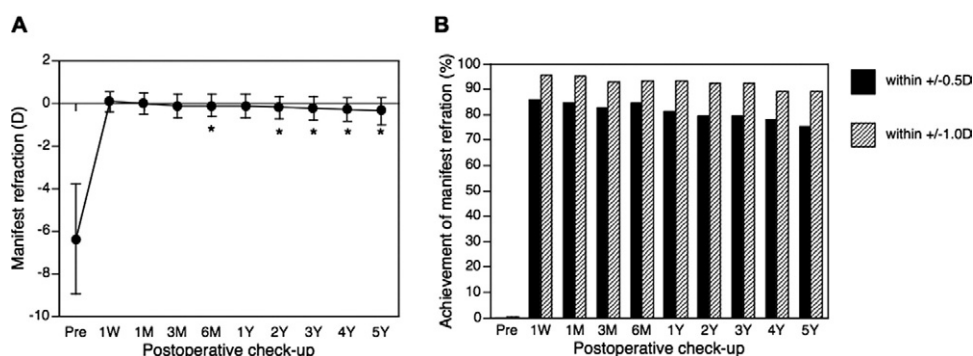


Figure 3. Changes in manifest refraction. **A**, Manifest refraction decreased shortly after surgery but showed faint and statistically significant regression for up to 5 years. **B**, Percentages of patients who revealed manifest refraction within ± 0.5 diopter (D) and ± 1.0 D were 86% and 96%, respectively, at 1 week after surgery, although both frequencies decreased thereafter. M = month; pre = preoperative examination; W = week; Y = year. * $P < 0.05$ compared with manifest refraction at 3 months after surgery.

mild but statistically significant regression thereafter was observed over the entire follow-up period. Such mild regression is thought to be caused by compensated epithelial hyperplasia after LASIK and by a slight anterior shift of the corneal curvature due to IOP. Another possibility is that the refractive regression may be caused partly by physiological changes due to aging such as the thickening and progression of nuclear sclerosis of the lens or axial elongation.^{26,27} That myopic eyes revealed axial elongation and progression of nuclear cataracts at an earlier age than emmetropic eyes²⁸ is consistent with the latter hypothesis.

Although there was a correlation between manifest refractions before and after surgery, the frequency of additional laser ablation showed no correlation with severity of the preoperative refractive error (data not shown). This is probably because eyes with high myopia tended to have less thickness of the residual corneal stroma for additional ablation.

The postoperative corneal thickness and postoperative IOP showed similar changes. The mean corneal thickness decreased 79.6 μm at the first assessment after surgery, compared with the preoperative value, and stayed unchanged thereafter up to the last evaluation. The mean postoperative IOP dropped by 4.0 mmHg at 1 week, compared with the preoperative value, and stayed unchanged thereafter, consistent with previous reports.^{29,30} In contrast, corneal endothelial cell counts were not affected by the surgery and remained statistically unchanged until 4 years after surgery. However, endothelial cell counts decreased significantly to 98.8% of the preoperative value at 5 years after surgery ($P = 0.006$). Normal corneal endothelial cells have been reported to decrease by 0.3% to 1.1% per year.^{31–33} Thus, a 1.2% loss in 5 years is within the normal physiological changes through aging, indicating that LASIK induced no harmful damage to the corneal endothelial cells.

Intraoperative and postoperative complications included epithelial defects (3.1%), free flap (0.1%), epithelial ingrowth (2.7%), diffuse lamellar keratitis (2.1%), and striae of the corneal flaps (13.3%). These incidences of complications were consistent with previous reports.^{34–38} Most of them were minor, and rare progressive cases were treated appropriately. Seven of 10 eyes with loss of BCVA of >2 lines were related to causes other than LASIK, such as the progression of cataracts and epithelial impairment due to dry eye. We found no obvious cause in the other 3 eyes; however, the eyes revealed neither signs of keratectasia nor any other complications related to LASIK.

We emphasize here that no serious complication that caused irreversible BCVA loss was observed among the patients analyzed. No eyes revealed severe stromal haze or keratectasia, affecting VA. We suspect that the stable results are due to the restrictions placed on patient selection and the ablation depth of the stroma. We have determined and strictly observed inclusion and exclusion criteria for LASIK candidates. When the present investigation began, we performed LASIK on several patients with high myopia of more than -12.0 D or suspicious keratoconus. Because the onset of postoperative keratectasia in cases with forme fruste keratoconus was reported from 1999 to 2000,^{39–41} we stopped performing LASIK on eyes with keratoconus, in-

cluding early or suspicious cases, in the middle of 2000. We also decided to measure the thickness of the stromal bed intraoperatively before laser ablation and to keep the residual corneal thickness at >250 μm after ablation in all eyes to avoid the risk of developing keratectasia.⁴² Indeed, the rate of patients who were contraindicated for LASIK for these reasons amounted to over 20% of those who visited our institute.⁴³ Because the incidence of LASIK surgery in our institute increased dramatically after 2000, the number of eyes with a preoperative SE of more than -12.0 D was limited to 19 (2.4%), and all of those eyes revealed relatively thick corneas (the thinnest was 523 μm), indicating that the residual stromal thickness of these eyes after laser ablation could not be much lower than about 250 μm . In addition, because changes in corneal shape due to the correction of high myopia decreased the quality of vision, especially night vision,^{44,45} we now no longer perform LASIK but, instead, recommend implantation of a phakic IOL⁴⁶ for patients with myopia of more than -12 D. We believe that observing these criteria is important to maintain the biomechanical integrity of the cornea and good vision after surgery. In addition, we always emphasize to our patients the importance of receiving regular postoperative examinations that enable us to diagnose and treat complications as early as possible. We will continue to look for the occurrence of late-onset keratectasia for as long as possible.

In conclusion, our investigation of long-term outcomes in a large number of patients indicates that LASIK is an effective and safe procedure. No severe late-onset or irreversible complications such as keratectasia or excessive endothelial cell loss developed. We recommend careful selection of appropriate candidates for surgery, and attention should be given to any postoperative complications, which should be treated appropriately in a timely manner.

References

1. Sandoval HP, de Castro LE, Vroman DT, Solomon KD. Refractive surgery survey 2004. *J Cataract Refract Surg* 2005; 31:221–33.
2. Solomon KD, Fernandez de Castro LE, Sandoval HP, et al. Refractive surgery survey 2003. *J Cataract Refract Surg* 2004; 30:1556–69.
3. Elder M, Leaming D, Hoy B. New Zealand cataract and refractive surgery survey 2004. *Clin Experiment Ophthalmol* 2006;34:401–10.
4. Yo C. Asian Americans: myopia and refractive surgery. *Int Ophthalmol Clin* 2003;43:173–87.
5. Duffey RJ, Leaming D. US trends in refractive surgery: 2004 ISRS/AAO survey. *J Refract Surg* 2005;21:742–8.
6. Ivarsen A, Moller-Pedersen T. LASIK induces minimal regrowth and no haze development in rabbit corneas. *Curr Eye Res* 2005;30:363–73.
7. Miyamoto T, Saika S, Okada Y, et al. Expression of cyclooxygenase-2 in corneal cells after photorefractive keratectomy and laser in situ keratomileusis in rabbits. *J Cataract Refract Surg* 2004;30:2612–7.
8. Philipp WE, Speicher L, Gottinger W. Histological and immunohistochemical findings after laser in situ keratomileusis in human corneas. *J Cataract Refract Surg* 2003;29:808–20.

9. Baldwin HC, Marshall J. Growth factors in corneal wound healing following refractive surgery: a review. *Acta Ophthalmol Scand* 2002;8:238–47.
10. Kaji Y, Soya K, Amano S, et al. Relation between corneal haze and transforming growth factor-beta1 after photorefractive keratectomy and laser in situ keratomileusis. *J Cataract Refract Surg* 2001;27:1840–6.
11. Wachtlin J, Langenbeck K, Schrunder S, et al. Immunohistology of corneal wound healing after photorefractive keratectomy and laser in situ keratomileusis. *J Refract Surg* 1999;15:451–8.
12. Shortt AJ, Bunce C, Allan BD. Evidence for superior efficacy and safety of LASIK over photorefractive keratectomy for correction of myopia. *Ophthalmology* 2006;113:1897–908.
13. O'Doherty M, O'Keeffe M, Kelleher C. Five year follow up of laser in situ keratomileusis for all levels of myopia. *Br J Ophthalmol* 2006;90:20–3.
14. Sun L, Liu G, Ren Y, et al. Efficacy and safety of LASIK in 10,052 eyes of 5081 myopic Chinese patients. *J Refract Surg* 2005;21(suppl):S633–5.
15. Lin JM, Tsai YY. Laser in situ keratomileusis for different degrees of myopia. *Acta Ophthalmol Scand* 2005;83:40–5.
16. Bilgihan K, Hondur A, Hasanreisoglu B. Laser subepithelial keratomileusis for myopia of -6 to -10 diopters with astigmatism with the MEL60 laser. *J Refract Surg* 2004;20:121–6.
17. Shahinian L Jr. Laser-assisted subepithelial keratectomy for low to high myopia and astigmatism. *J Cataract Refract Surg* 2002;28:1334–42.
18. Payvar S, Hashemi H. Laser in situ keratomileusis for myopic astigmatism with the Nidek EC-5000 laser. *J Refract Surg* 2002;18:225–33.
19. Chitkara DK, Rosen E, Gore C, et al. Tracker-assisted laser in situ keratomileusis for myopia using the autonomous scanning and tracking laser: 12-month results. *Ophthalmology* 2002;109:965–72.
20. Yang CN, Shen EP, Hu FR. Laser in situ keratomileusis for the correction of myopia and myopic astigmatism. *J Cataract Refract Surg* 2001;27:1952–60.
21. Bokobza Y, Burtin T. Clinical outcome after in situ laser keratomileusis (LASIK) for myopia: a series of 390 eyes [in French]. *J Fr Ophtalmol* 2000;23:870–8.
22. Rashad KM. Laser in situ keratomileusis for myopic astigmatism. *J Refract Surg* 1999;15:653–60.
23. Lindstrom RL, Hardten DR, Chu YR. Laser in situ keratomileusis (LASIK) for the treatment of low, moderate, and high myopia. *Trans Am Ophthalmol Soc* 1997;95:285–96.
24. Sekundo W, Bonicke K, Mattausch P, Wiegand W. Six-year follow-up of laser in situ keratomileusis for moderate and extreme myopia using a first-generation excimer laser and microkeratome. *J Cataract Refract Surg* 2003;29:1152–8.
25. Asano-Kato N, Toda I, Hori-Komai Y, et al. Risk factors for insufficient fixation of microkeratome during laser in situ keratomileusis. *J Refract Surg* 2002;18:47–50.
26. Wong TY, Foster PJ, Johnson GJ, Seah SK. Refractive errors, axial ocular dimensions, and age-related cataracts: the Tanjong Pagar survey. *Invest Ophthalmol Vis Sci* 2003;44:1479–85.
27. Fernandes A, Bradley DV, Tigges M, et al. Ocular measurements throughout the adult life span of rhesus monkeys. *Invest Ophthalmol Vis Sci* 2003;44:2373–80.
28. Saw SM, Gazzard G, Shih-Yen EC, Chua WH. Myopia and associated pathological complications. *Ophthalmic Physiol Opt* 2005;25:381–91.
29. Rashad KM, Bahnassy AA. Changes in intraocular pressure after laser in situ keratomileusis. *J Refract Surg* 2001;17:420–7.
30. Bayraktar S, Bayraktar Z. Central corneal thickness and intraocular pressure relationship in eyes with and without previous LASIK: comparison of Goldmann applanation tonometer with pneumatonometer. *Eur J Ophthalmol* 2005;15:81–8.
31. Cheng H, Jacobs PM, McPherson K, Noble MJ. Precision of cell density estimates and endothelial cell loss with age. *Arch Ophthalmol* 1985;103:1478–81.
32. Hashemian MN, Moghimi S, Fard MA, et al. Corneal endothelial cell density and morphology in normal Iranian eyes. *BMC Ophthalmol* [serial online] 2006;6:9. Available at: <http://www.biomedcentral.com/1471-2415/6/9>. Accessed July 5, 2007.
33. Bourne WM, Nelson LR, Hodge DO. Central corneal endothelial cell changes over a ten-year period. *Invest Ophthalmol Vis Sci* 1997;38:779–82.
34. Asano-Kato N, Toda I, Hori-Komai Y, et al. Epithelial ingrowth after laser in situ keratomileusis: clinical features and possible mechanisms. *Am J Ophthalmol* 2002;134:801–7.
35. Wang MY, Maloney RK. Epithelial ingrowth after laser in situ keratomileusis. *Am J Ophthalmol* 2000;129:746–51.
36. Linebarger EJ, Hardten DR, Lindstrom RL. Diffuse lamellar keratitis: diagnosis and management. *J Cataract Refract Surg* 2000;26:1072–7.
37. Noda-Tsuruya T, Toda I, Asano-Kato N, et al. Risk factors for development of diffuse lamellar keratitis after laser in situ keratomileusis. *J Refract Surg* 2004;20:72–5.
38. Asano-Kato N, Toda I, Tsuruya T, et al. Diffuse lamellar keratitis and flap margin epithelial healing after laser in situ keratomileusis. *J Refract Surg* 2003;19:30–3.
39. Seiler T, Quurke AW. Iatrogenic keratectasia after LASIK in a case of forme fruste keratoconus. *J Cataract Refract Surg* 1998;24:1007–9.
40. Schmitt-Bernard CF, Lesage C, Arnaud B. Keratectasia induced by laser in situ keratomileusis in keratoconus. *J Refract Surg* 2000;16:368–70.
41. Joo CK, Kim TG. Corneal ectasia detected after laser in situ keratomileusis for correction of less than -12 diopters of myopia. *J Cataract Refract Surg* 2000;26:292–5.
42. Seiler T, Koufala K, Richter G. Iatrogenic keratectasia after laser in situ keratomileusis. *J Refract Surg* 1998;14:312–7.
43. Hori-Komai Y, Toda I, Asano-Kato N, Tsubota K. Reasons for not performing refractive surgery. *J Cataract Refract Surg* 2002;28:795–7.
44. Holladay JT, Dudeja DR, Chang J. Functional vision and corneal changes after laser in situ keratomileusis determined by contrast sensitivity, glare testing, and corneal topography. *J Cataract Refract Surg* 1999;25:663–9.
45. Knorz MC, Hugger P, Jendritzka A, Liermann A. Twilight visual acuity after correction of myopia with LASIK [in German]. *Ophthalmologie* 1999;96:711–6.
46. Asano-Kato N, Toda I, Hori-Komai Y, et al. Experience with the Artisan phakic intraocular lens in Asian eyes. *J Cataract Refract Surg* 2005;31:910–5.

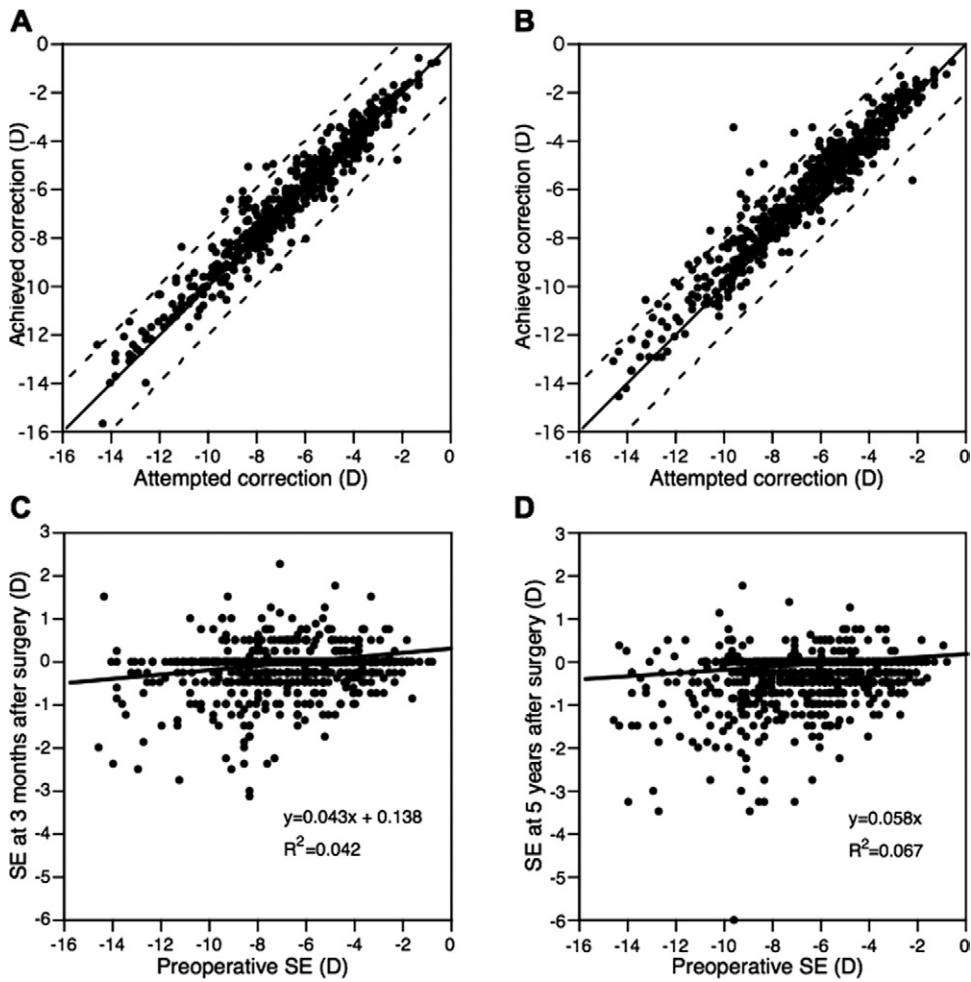


Figure 4. Achievement of correction. **A**, Differences between achieved and attempted correction were within ± 0.5 diopter (D) in 82.6%, ± 1.0 D in 93.1%, and ± 2.0 D in 98.5% of eyes at 3 months after surgery. **B**, Differences between attempted and achieved correction were within ± 0.5 D in 75.2%, ± 1.0 D in 89.0%, and ± 2.0 D in 97.9% of eyes at 5 years after surgery. **C**, **D**, Preoperative spherical equivalent (SE) and manifest refraction are correlated at 3 months ($P < 0.001$) and 5 years ($P < 0.001$) after surgery.

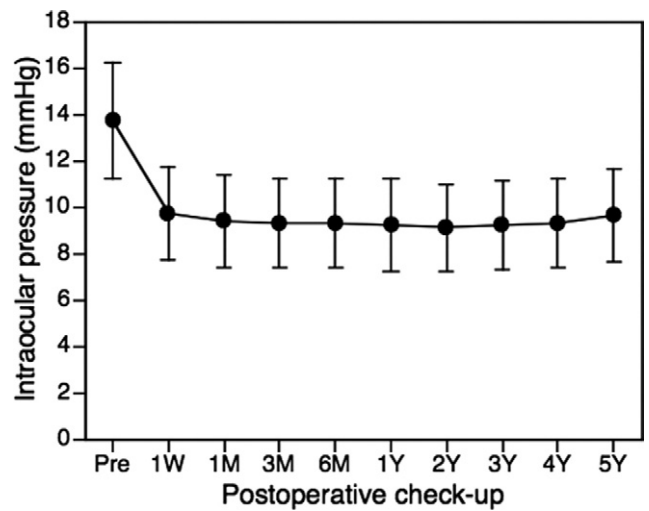


Figure 5. Changes in corneal intraocular pressure, which decreased by 4.0 mmHg at 1 week after surgery compared with the preoperative value and remained stable thereafter. M = month; pre = preoperative examination; W = week; Y = year.

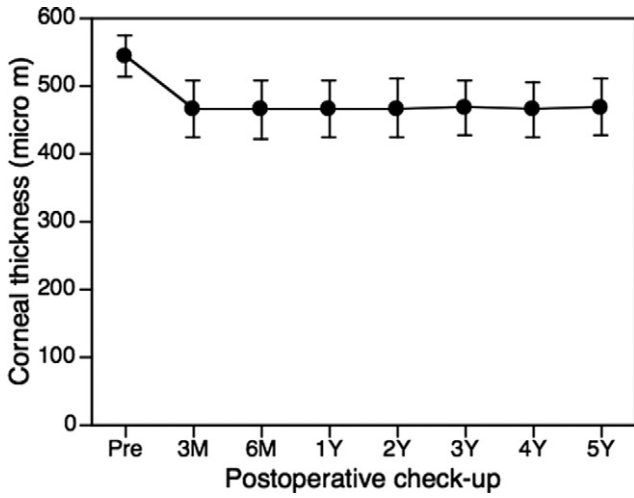


Figure 6. Changes in corneal thickness, which decreased by 76.9 μm at 3 months after surgery compared with the preoperative value and remained stable thereafter. M = month; pre = preoperative; Y = year.

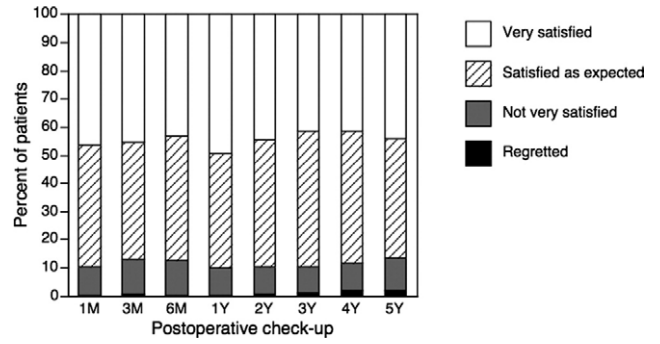


Figure 8. Patient satisfaction. Approximately 90% of patients answered that they were satisfied or very satisfied with the outcome of their surgery throughout the examination period. M = month; Y = year.

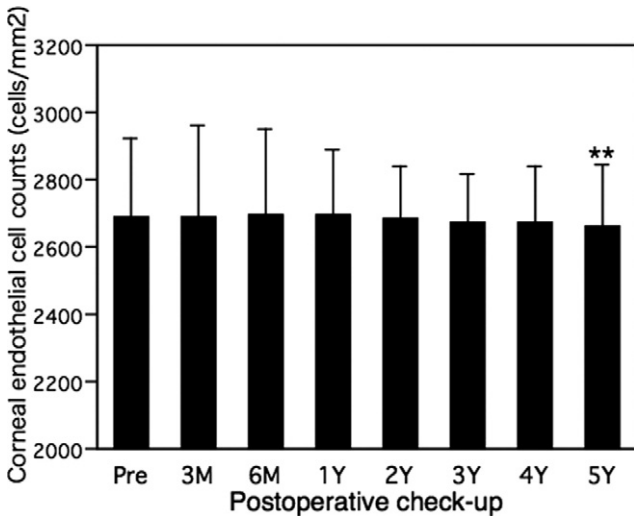


Figure 7. Changes in corneal endothelial cell counts, which showed no statistical decrease until 4 years after surgery but were significantly decreased at the 5-year evaluation ($P = 0.006$). M = month; pre = preoperative examination; Y = year.